

Guttate Psoriasis Following Presumed Coxsackievirus A

Kevin M. Rychik, BS; Naghmeh Yousefzadeh, MD; Alan T. Glass, MD

PRACTICE POINTS

- Inquire about any illnesses preceding dermatologic diseases.
- There may be additional microbial triggers for dermatologic diseases.

Guttate psoriasis is a variant of psoriasis characterized by small, 2- to 10-mm, raindroplike lesions on the skin. Guttate psoriasis is commonly triggered by group A streptococcal pharyngitis. We describe a novel case of guttate psoriasis following presumed coxsackievirus A hand-foot-and-mouth disease (HFMD). A 56-year-old woman presented with a vesicular erythematous rash on the hands, feet, and lips. The patient was clinically diagnosed with coxsackievirus A infection after presenting with a sore throat and a new-onset rash that lasted for 1 to 2 days. Physical examination revealed vesicles in the oral cavity and erythematous vesicles and papules on the extensor surfaces of the hands and feet. One month later, the patient returned citing new red skin lesions on the abdomen and groin. A clinical diagnosis of guttate psoriasis was made, which was confirmed via biopsy of an abdominal skin lesion. The patient denied any history of psoriasis.

Cutis. 2019;104:248-249.

There are 4 variants of psoriasis: plaque, guttate, pustular, and erythroderma (in order of prevalence).² Guttate psoriasis is characterized by small, 2- to 10-mm, raindroplike lesions on the skin.¹ It accounts for approximately 2% of total psoriasis cases and is commonly triggered by group A streptococcal pharyngitis or tonsillitis.^{3,4}

Hand-foot-and-mouth disease (HFMD) is an illness most commonly caused by a coxsackievirus A infection but also can be caused by other enteroviruses.^{5,6} Coxsackievirus is a serotype of the *Enterovirus* species within the *Picornaviridae* family.⁷ Hand-foot-and-mouth disease is characterized by a brief fever and vesicular rashes on the palms, soles, or buttocks, as well as oropharyngeal ulcers.⁸ Typically, the rash is benign and short-lived.⁹ In rare cases, neurologic complications develop. There have been no reported cases of guttate psoriasis following a coxsackievirus A infection.

The involvement of coxsackievirus B in the etiopathogenesis of psoriasis has been previously reported.¹⁰ We report the case of guttate psoriasis following presumed coxsackievirus A HFMD.

Case Report

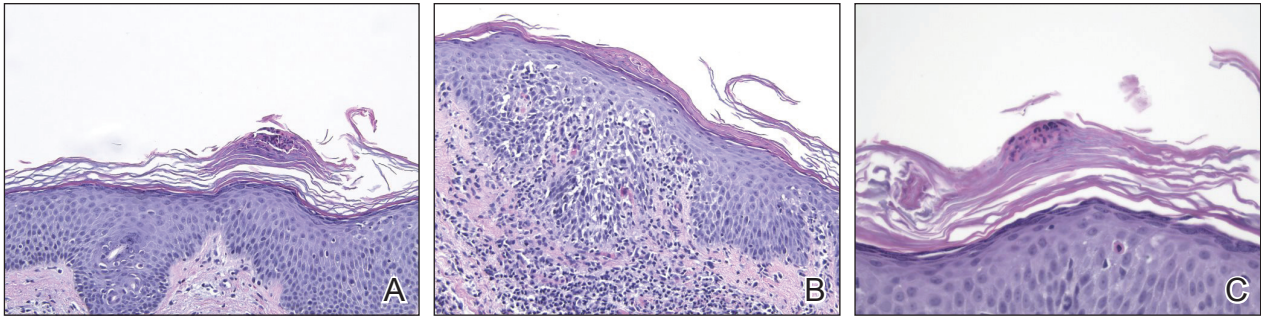
A 56-year-old woman presented with a vesicular rash on the hands, feet, and lips. The patient reported having a sore throat that started around the same time that the rash developed. The severity of the sore throat was rated as moderate. No fever was reported. One day prior, the patient's primary care physician prescribed a tapered course of prednisone for the rash. The patient reported a medical history of herpes zoster virus, sunburn, and genital herpes. She was taking clonazepam and had a known allergy to penicillin.

Physical examination revealed erythematous vesicular and papular lesions on the extensor surfaces of the hands and feet. Vesicles also were noted on the vermilion border of the lip. Examination of the patient's mouth showed blisters and shallow ulcerations in the oral cavity. A

Mr. Rychik is from the Sackler School of Medicine, New York State/American Program of Tel Aviv University, New York. Dr. Yousefzadeh is from the Department of Dermatology, SUNY Downstate Medical Center, Brooklyn, and DermPath Diagnostics, Port Chester, New York. Dr. Glass is from 57 West Dermatology, New York, New York.

The authors report no conflict of interest.

Correspondence: Alan T. Glass, MD, 57 W 57th St, Ste 1109, New York, NY 10019 (skindr@optonline.net).



A–C, A shave biopsy showed an acanthotic epidermis with foci of spongiosis and hypergranulosis covered by mounds of parakeratosis infiltrated by neutrophils (H&E, original magnifications $\times 10$, $\times 10$, and $\times 20$, respectively).

clinical diagnosis of coxsackievirus A HFMD was made, and the treatment plan included triamcinolone acetone ointment 0.025% applied twice daily for 2 weeks and oral valacyclovir hydrochloride 1 g taken 3 times daily for 7 days. A topical emollient also was recommended for the lips when necessary. The lesions all resolved within a 2-week period with no sequela.

The patient returned 1 month later, citing newer red abdominal skin lesions. Fever was denied. She reported that both prescribed treatments had not been helping for the newer lesions. She noticed similar lesions on the groin and brought them to the attention of her gynecologist. Physical examination revealed salmon pink papules and plaques with silvery scaling involving the abdomen, bilateral upper extremities and ears, and scalp. The patient was then clinically diagnosed with guttate psoriasis. A shave biopsy of a representative lesion on the abdomen was performed. The treatment plan included betamethasone dipropionate cream 0.05% applied twice daily for 2 weeks, clobetasol propionate solution 0.05% applied twice daily for 14 days (for the scalp), and hydrocortisone valerate cream 0.2% applied twice daily for 14 days (for the groin).

The skin biopsy shown in the Figure was received in 10% buffered formalin, measuring $5 \times 4 \times 1$ mm of skin. Sections showed an acanthotic epidermis with foci of spongiosis and hypergranulosis covered by mounds of parakeratosis infiltrated by neutrophils. Superficial perivascular and interstitial lymphocytic inflammation was present. Tortuous blood vessels within the papillary dermis also were present. Results showed psoriasiform dermatitis with mild spongiosis. Periodic acid–Schiff stain did not reveal any fungal organisms. These findings were consistent with a diagnosis of guttate psoriasis.

The patient then returned 1 month later mentioning continued flare-ups of the scalp as well as newer patches on the arms and hands that were less eruptive and faded more quickly. The plaques in the groin area had resolved. Physical examination showed fewer pink papules and plaques with silvery scaling on the abdomen, bilateral upper extremities and ears, and scalp. Topical medications

were continued, and possible apremilast therapy for the psoriasis was discussed.

Comment

Enterovirus-derived HFMD likely is caused by coxsackievirus A. Current evidence supports the theory that guttate psoriasis can be environmentally triggered in genetically susceptible individuals, often but not exclusively by a streptococcal infection. The causative agent elicits a T-cell-mediated reaction leading to increased type 1 helper T cells, IFN- γ , and IL-2 cytokine levels. HLA-Cw*0602–positive patients are considered genetically susceptible and more likely to develop guttate psoriasis following an environmental trigger. Based on the coincidence in timing of both diagnoses, this reported case of guttate psoriasis may have been triggered by a coxsackievirus A infection.

REFERENCES

- Langley RG, Krueger GG, Griffiths CE. Psoriasis: epidemiology, clinical features, and quality of life. *Ann Rheum Dis*. 2005;64(suppl 2):ii18–ii23.
- Sarac G, Koca IT, Baglan T. A brief summary of clinical types of psoriasis. *North Clin Istanbul*. 2016;1:79–82.
- Prinz JC. Psoriasis vulgaris—a sterile antibacterial skin reaction mediated by cross-reactive T cells? an immunological view of the pathophysiology of psoriasis. *Clin Exp Dermatol*. 2001;26:326–332.
- Telfer N, Chalmers RJ, Whale K, et al. The role of streptococcal infection in the initiation of guttate psoriasis. *Arch Dermatol*. 1992;128:39–42.
- Cabrero M, Tarragó D, Muñoz-Almagro C, et al. Molecular epidemiology of enterovirus 71, coxsackievirus A16 and A6 associated with hand, foot and mouth disease in Spain. *Clin Microbiol Infect*. 2014;20:O150–O156.
- Li Y, Chang Z, Wu P, et al. Emerging enteroviruses causing hand, foot and mouth disease, China, 2010–2016. *Emerg Infect Dis*. 2018;24:1902–1906.
- Seitonen J, Shakeel S, Susi P, et al. Structural analysis of coxsackievirus A7 reveals conformational changes associated with uncoating. *J Virol*. 2012;86:7207–7215.
- Wu Y, Yeo A, Phoon M, et al. The largest outbreak of hand, foot and mouth disease in Singapore in 2008: the role of enterovirus 71 and coxsackievirus A strains. *Int J Infect Dis*. 2010;14:E1076–E1081.
- Tesini BL. Hand-foot-and-mouth-disease (HFMD). May 2018. <https://www.msdmanuals.com/professional/infectious-diseases/enteroviruses/hand-foot-and-mouth-disease-hfmd>. Accessed September 25, 2019.
- Korzhoza TP, Shyrobokov VP, Koliadenko VH, et al. Coxsackie B viral infection in the etiology and clinical pathogenesis of psoriasis [in Ukrainian]. *Lik Sprava*. 2001;54–58.